

Chapter 6 Skeletal System

Functions of the skeletal system/bone

- | | |
|---------------------|--|
| 1. Support | skeletal system is the internal framework of the body |
| 2. Protection | protects internal organs |
| 3. Movement | muscles & bones work together.
muscles move bones as levers |
| 4. Mineral storage | bones are made up of minerals, especially calcium
phosphate |
| 5. Blood cell frmtn | red marrow contains blood cells |

Bone is classified by...

How the tissue is organized

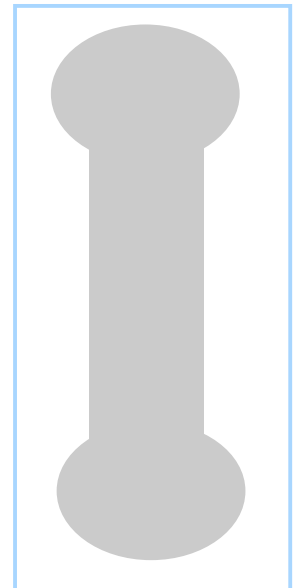
- | | |
|--------------|---|
| Compact Bone | This forms the outer surface of bone.
Dense
AKA: cortical bone |
| Spongy Bone | Network of interwoven spicules called trabeculae
Lots of space
Made of same stuff as compact bone, arranged differently |

Bone shape (4 general shapes)

- | | |
|-----------------|---|
| Long Bones | Most appendicular bones are long bones
Femur, metacarpals, etc... |
| Flat Bones | Thin & flat, broad, curved
Cranial bones, sternum, ribs, scapula |
| Short Bones | Cuboidal, box-like
Carpal & tarsal bones
Includes “sesamoid bones”, which are bones that form
within a tendon (where stress is on a tendon). These vary! |
| Irregular Bones | Complex shape
Vertebrae, os coxae, maxilla, ethmoid, etc... |

Bone Structure

LONG BONES form into a bone with distinct regions...the DIAPHYSIS, EPIPHYSIS, METAPHYSIS and MEDULLARY CAVITY. The diaphysis is the shaft of the long bone, while the epiphyses are the rounded ends. The metaphysis is the area where the diaphysis and epiphyses meet. This region surrounds the epiphyseal plate, which is on the inside. The medullary cavity, located on the inside of the bone, runs at least along the



length of the diaphysis, but it can also go up into the epiphysis. It is lined by spongy bone and is hollow space.

MEMBRANES surround every bone. The membrane is a double layer called the PERIOSTEUM, while the ENDOSTEUM lines the trabeculae of internal spongy bone. The periosteum is made up of two layers...the outer layer is made up of DICT so that tendons and ligaments can insert. The inner layer is made up of osteoblasts and osteoclasts. How does the periosteum bind to the bone? It uses perforating fibers! The periosteum is richly supplied with nerve fibers, blood vessels and lymphatic vessels.

The ENDOSTEUM is not as dense as the periosteum and is made up of areolar CT. It also contains osteoblasts and osteoclasts.

Structure of compact bone (pg 183)

Compact bone is made up of OSTEONS, the functional unit of compact bone. Osteons are cylinders of bone tissue that run parallel to the long axis of a long bone. Each osteon surrounds a central canal (elevator shaft) that transmits blood vessels and nerve that serve the needs of the osteon's cells. While the central canals go up and down, the perforating canals run perpendicular to the long axis, connecting the blood and nerve supply of the PERIOSTEUM to the central canal. Think of Willie Wonka's elevator system that would go up and down and sideways. These canals, like all other internal bone cavities, are lined with endosteum.

The osteon up close!

Each osteon is made up of concentric layers of matrix called lamellae. Think of a telescope! Running through this matrix are collagen fibers...the alternating direction of the collagen fibers in each layer of lamellae give the osteon greater strength!

Osteocytes occupy spaces called lacunae (lac=hollow, una=little) at the junctions of the lamellae. Hairlike canals called canaliculi connect the lacunae to each other and to the central canal. This is how they get their nutrients. (page 183)

What is an osteocyte?	Mature bone cell
	Resides in the lacunae (lacuna, singular)
	The lacunae are between the lamellae

What about other lamallae? Osteons can't fill the whole space because they are round. Think of apples in a box...there is lots of space around the apples! Something has to fill this space around the osteons...what is it? Two types of lamellae...circumferential and interstitial.

CIRCUMFERENTIAL LAMALLAE is deep to the periosteum and superficial to the medullary cavity. Circumferential lamellae look like the rings of a tree and surround the group of osteons on the circumference of the diaphysis.

INTERSTITIAL LAMALLAE lie between the osteons. Essentially interstitial lamellae are incomplete osteons (old ones).

RED MARROW contains hematopoetic tissue and is the site of blood cell production. The locations vary based on developmental stage. In infants, who need a greater level of blood cell production, the red marrow is in the medullary cavities of all long bones and in all areas of spongy bones. In adults the red marrow is located in the proximal heads of the humerus and femur and in the diploe of flat bones (the skull, os coxa and sternum). Diploe is the spongy bone of flat bone. So, what fills the remaining areas of the long bones? Yellow marrow (lipid), fills the space and it may revert to red marrow if needed due to blood loss.

The Matrix

The bone has both organic and inorganic components.

The ORGANIC COMPONENT of the matrix is the OSTEOD. It comprises 1/3 of the matrix and is composed of ground substance and fibers.

ground substance	made up of proteoglycans and glycoproteins
fibers	collagen, which are secreted by osteoblasts
value of osteod	provides flexibility and tensile strength
resists	collage resists stretching

The INORGANIC COMPONENT of the matrix are the mineral salts, which make up 2/3 of the matrix by mass.

made up of	primarily calcium phosphates
which is...	tiny salt crystals packed tightly arnd collagen fibers
value of mineral salts	provides hardness of bone
resists	compression

Bone Physiology

Bone formation begins around the 8th week of development. At this stage, the skeletal elements are fibrous membranes and hyaline cartilage. There are two different methods of ossification, one for each type. The fibrous membrane will become bone via INTRAMENBRANEOUS OSSIFICATION, while the hyaline cartilage will become bone via ENDOCHONDRYL OSSIFICATION.

With intramembraneous ossification, bone forms within the fibrous membrane. This is generally for skull bones and clavicles.

With endochondryl ossification, bone forms from the cartilaginous model. This occurs in long bones, short bones, irregular bones)

Intramembraneous ossification (page 184)

1. Ossification center appears in the fibrous connective tissue membrane. It is formed when mesenchymal cells cluster near the center of the membrane and differentiate into osteoblasts.
2. Bone matrix (osteoid) is secreted within the fibrous membrane. In this stage, osteod gets laid down by the osteoblasts, which mineralizes within a few days. Trapped osteoblasts become osteocytes.
3. Vascularization...woven bone and periosteum form in this stage. Blood vessels grow into the region and the matrix forms around the blood vessels, forming woven bone. The osteoid gets laid down in a random network of trabeculae...this is not the same as spongy bone. The periosteum forms as the vascularized mesenchyme condense on the external membrane faces. Not bone yet!
4. Remodeling...bony collar of compact bone forms and red marrow appears in this stage. The bony collar forms as the trabeculae deep to the periosteum thicken and merge. This is later replaced by mature lamellar compact bone. The spongy bone (diploe) forms when woven bone is replaced by mature trabeculae...its vascular tissue becomes red marrow.

Endochondryl ossification (cartilage model)

This process is more complex because the hyaline cartilage model must be broken down as ossification proceeds. It begins in the 2nd month of development and has 6 steps.

1. Periosteum formation. Blood vessels invade the perichondrium of the cartilage model and convert to periosteum. The inner mesenchymal cells become osteoblasts.
2. Bony collar formation. A bony collar forms around the diaphysis of the hyaline cartilage model. It is formed when osteoblasts in the periosteum lay down osteod along the diaphysis of the model.
3. Cartilage cavitation overlaps bony collar formation. In this stage, the primary ossification center forms at the center of the diaphysis. Chondrocytes grow larger (hypertrophy), and as they grow larger they start calcifying the cartilage around them. As they grow they require more nutrients which they do not get due to calcification...so they die, leaving behind cavities. However, the bony collar keeps the hyaline cartilage stable.
4. Periosteal bud invades the internal cavities and spongy bone forms. The periosteal bud is made up of arteries, veins, lymphatics, red marrow elements, osteoblasts, osteoclasts and nerves. The entering osteoclasts partially erode the calcified cartilage matrix and the osteoblasts secrete osteoid around the remaining cartilage forming the earliest version of spongy bone.
5. The diaphysis elongates and a medullary cavity forms. In this stage osteoclasts erode the newly-formed spongy bone, forming a medullary cavity. The diaphysis continues to lengthen and cartilage cells in the epiphysis continue to grow. In this stage ossification "chases" cartilage formation along the length of the shaft.
6. Epiphyseal ossification occurs around birth. At this point the epiphysis start forming secondary ossification centers in the same way as the diaphysis, with two exceptions: no medullary cavity forms so the spongy bone is retained, and there is

no bony collar formation. The hyaline cartilage remains on the articular surface of the long bones (ends of long bones) and at the epiphyseal plate, which is temporary.

Bone Growth (lengthening of bone) – page 186-187.

Bone growth occurs until the late teens/early 20s. It occurs at the epiphyseal plate.

Bone growth takes place because cartilage on the epiphyseal plate continues to grow, pushing the epiphyses away from the diaphysis. The older chondrocytes hypertrophy and their lacunae erode and enlarge. Subsequently the surrounding cartilage matrix calcifies. Osteoclasts and osteoblasts convert cartilage to bone. Osteoclasts remove bone at diaphysis side extending the medullary cavity. Cartilage formation and replacement continue at the same rate and growth continues to occur. At the end of the growth, chondrocyte division slows and bone formation “catches up”. The epiphyseal plate closes.

Bone Growth (widening of bone)

The widening of bone does not involve cartilage. It is used to increase the diameter of bone, producing a thicker, stronger bone that is not too heavy. The osteoblasts in perosteum lay down a layer of bone on the external surface while the osteoclasts in endosteum remove bone from the internal surface. The result is the medullary cavity gets wider and the diameter increases. The thickness of the bone wall increases, due to the laying down activity of the osteoblasts outpacing that of the osteoclasts.

Bone Growth Regulation

Bone growth is regulated primarily by hormones. In childhood, growth is stimulated by the pituitary GROWTH HORMONE, while the THYROID GLAND modulates the effect of the growth hormone. Later, at the time of a growth spurt or at the end of it when the epiphyseal plate closes, SEX HORMONES regulate growth (estrogen and testosterone).

Bone Remodeling

For bone remodeling to occur, bone deposit and resorption occur at the same rate. What controls bone remodeling? HORMONAL MECHANISM maintains calcium homeostasis in the blood; and RESPONSE TO MECHANICAL STRESS keeps bones strong where stresses are acting (Wolff's Law).

Wolff's Law stipulates that a bone grows or remodels in response to the demands placed on it.

Some facts about bone remodeling:

- Occurs throughout life
- Constantly changing, the skeleton is replaced frequently
 - Spongy bone replaced every 3-4 years
 - Compact bone replaced every 10 years
- Influencing factors
 - Mineral needs of the body
 - Stresses on bone

- Mechanisms
 - Hormonal (relates to mineral needs). PARATHYROID HORMONE (from the parathyroid gland) stimulates bone resorption by stimulating osteoclast activity. Calcium is released [into the blood in response to low calcium levels](#). CALCITONIN (from the thyroid gland) stimulates bone deposition by stimulating osteoblast and inhibiting osteoclasts. [Calcitonin activates in response to high blood calcium levels](#). It has a limited effect on adults.
 - Mechanical (relates to stresses). Bone is laid down in regions where forces are the greatest...
 - walls of shafts of long bones
 - center of shaft more than the ends
 - trabeculae form along lines of stress
 - bony projections occur at muscle attachment